

## Chronic diarrhea in children : Part II. Clinical Approach and Management

Mohamed I El Mouzan

Department of Pediatrics, College of Medicine and King Khaled University Hospital,  
King Saud University, Riyadh, Saudi Arabia

Click [here](#) for correspondence address and email

### Abstract

Chronic diarrhea is a complex symptom. The clinical approach and management should be based on pathophysiological considerations and stepwise laboratory investigations. In infants with severe malnutrition, nutritional support is a priority in the management of this condition.

### How to cite this article:

El Mouzan MI. Chronic diarrhea in children : Part II. Clinical Approach and Management. Saudi J Gastroenterol 1995;1:81-6

### How to cite this URL:

El Mouzan MI. Chronic diarrhea in children : Part II. Clinical Approach and Management. Saudi J Gastroenterol [serial online] 1995 [cited 2010 Aug 25];1:81-6. Available from: <http://www.saudijgastro.com/text.asp?1995/1/2/81/34045>

### Clinical Approach

The symptom of chronic diarrhea is annoying for most parents, patients and physicians. The differential diagnosis of this problem is extensive, requiring an organized approach. The history and physical examination, when properly performed are the foundations for definitive diagnosis. Data and clues gathered from a detailed, relevant history and physical examination lead to the diagnosis and help in the choice of more appropriate diagnostic tests or procedures in the majority of cases.

### The history:

*The family history* may be helpful. The presence of similar symptoms in a parent, sibling, or relative suggests an inherited cause of chronic diarrhea.

*The age of onset* is important to consider. Certain disorders have typical (but not exclusive) age of onset. For example, chronic diarrhea starting shortly after birth suggests a congenital or an inherited disorder (eg. Microvillous atrophy, lactose intolerance, glucose-galactose malabsorption, chloride diarrhea, cystic fibrosis); whereas other conditions (eg. celiac disease, cow's milk protein intolerance) usually present later. Finally, inflammatory bowel diseases usually present in older children,

and adults. *The mode of onset* is also important. Chronic diarrhea following acute gastroenteritis suggests the postenteritis syndrome, or a prolonged infection. An acute mode of onset is usually suggestive of cow's milk protein intolerance or disaccharidase deficiency, whereas a more gradual mode of onset is more characteristic of celiac disease, tropical sprue, or cystic fibrosis.

*The dietary history* may be extremely helpful especially when correlated with the onset of diarrhea. For example, in an exclusively breast-fed infant with chronic diarrhea, celiac disease is not a consideration and cow's milk protein intolerance is very unlikely. Similarly, clinical presentation of celiac disease, cow's milk protein intolerance, disaccharidase deficiency occurs after exposure to gluten, cow's milk, and disaccharide-containing food respectively. Consequently, when diarrhea starts before the introduction of gluten (for example), celiac disease is not a diagnostic consideration. Dietary history should also include specific questions on the type of diet given throughout the illness. Children with diarrhea are frequently put on prolonged half-strength formula feedings which cause malnutrition and worsen the diarrhea. *The appetite* is preserved and may even be increased in patients with cystic fibrosis. This contrasts with the usual anorexia associated with celiac disease and inflammatory bowel diseases.

*Growth and developmental history* in patients with chronic diarrhea is essential. Normal weight gain and developmental milestones suggest a benign disorder such as irritable bowel syndrome, dietary indigestion, parasitic infestation or carbohydrate intolerance in older children. Chronic diarrhea with failure to thrive or even weight loss has a more serious cause and usually requires more detailed investigations. *The history of repeated infections* suggests immune deficiency or cystic fibrosis and *a history of previous abdominal surgery* may indicate anatomical or structural causes. *The type of diarrhea* is very important. However, for many parents, accurate description of the character of stool is difficult and physicians should inspect stool samples to ascertain their type and character. The presence of undigested food particles is probably of no pathologic significance and suggests increased transit. Watery diarrhea may indicate carbohydrates malabsorption, chloride diarrhea, or secretory diarrhea. Steatorrhea is a feature of generalized or selective fat malabsorption. The stools of patients with cystic fibrosis or celiac disease are usually described as large, foul-smelling, oily or greasy, foamy and pale, indicating steatorrhea. Other conditions associated with steatorrhea include intestinal lymphangiectasia, abetalipoproteinemia and bile acid malabsorption. The presence of blood and mucus in the stools indicates colitis (cow's milk protein intolerance in infants and infectious, ulcerative, or crohn's colitis in older children).

### **The Physical Examination:**

In addition to complete physical examination, a systematic search for signs associated with certain conditions may be helpful. Assessment of growth and development and nutritional status should separate patients who are normal from those who have failure to thrive. The importance of examining the stool has already been mentioned. Certain physical signs may help orient the diagnosis. Presence of periorificial skin lesions suggests acrodermatitis enteropathica. Ptosis suggests tumors especially neuroblastoma. Peripheral edema raises the possibility of protein-losing enteropathy or severe malnutrition. Clubbing of the fingers is usually associated with chronic

conditions such as cystic fibrosis or inflammatory bowel diseases. Retinitis pigmentosa and ataxia are known signs of abetalipoproteinemia, and arthralgia or arthritis is associated with inflammatory bowel diseases. Signs of fat soluble vitamin deficiency such as skin bruises (Vit K) and rickets (Vit D) may be present in patients with steatorrhea.

### **The Laboratory Investigations:**

The number of tests available for the diagnosis of chronic diarrhea is very large and it is impossible to perform all of them in all patients. The selection of tests and procedures should be individualized and based on data obtained from the history and physical examination. A scheme of investigation is suggested with *a list of routine or first line tests* to be performed in all children. Special tests or procedures (second line) may be indicated based on the history, physical examination, and results of first line tests [Table - 1]. Routine tests may either be diagnostic (eg. urinary tract infection, giardiasis, bacterial infections) or may serve as screening for certain conditions. For example, positive occult blood suggests colitis (cow's milk protein intolerance in infants, infective colitis, or inflammatory bowel disease). Likewise, low stool pH, positive fat globules and positive-reducing substances suggest malabsorption; whereas, peripheral eosinophilia is associated with food allergy and allergic (eosinophilic) gastroenteropathies. Lymphocytopenia and hypogammaglobulinemia are associated with lymphangiectasia, and acanthocytosis is found in abetalipoproteinemia. Finally, ESR may be high in inflammatory bowel disease.

*The second line tests* may also be diagnostic or provide further supportive data for the diagnosis. For example, a low serum protein and albumin suggests protein-losing enteropathies; a low serum carotene level is associated with fat malabsorption; low cholesterol and triglycerides blood levels suggest abetalipoproteinemia. Similarly, an abnormal D-xylose test suggests mucosal disease and various antigliadin antibodies are used to screen for celiac disease. Other tests may be diagnostic. For example, Hypochloremic metabolic alkalosis in a patient with chronic or recurrent diarrhea is practically diagnostic of chloride diarrhea; a low zinc blood level confirms the diagnosis of acrodermatitis enteropathica; and sweat chloride test is the diagnostic test for cystic fibrosis. Barium meal with small bowel follow through is useful to identify structural or anatomical anomalies of the intestine (eg. malrotation, short bowel, fistulae), and barium enema may show signs of colitis. More invasive procedures may be indicated to confirm the diagnosis suggested by previous tests. Small bowel biopsy (peroral or endoscopic) and histopathology are necessary for the diagnosis of mucosal diseases such as celiac disease, abetalipoproteinemia, intestinal lymphangiectasia, cow's milk protein or other food allergic enteritis and eosinophilic enteropathies. Similarly, rectosigmoidoscopy or colonoscopy and histopathology may be helpful in the diagnosis of colitis and Hirschsprung's disease. Elimination and challenge tests are necessary for the diagnosis of certain conditions such as food allergy and celiac disease.

### **Chronic Diarrhea-Malnutrition**

The most important complication of chronic diarrhea is the development of failure to thrive, malnutrition, and growth failure. Apart from the syndrome of chronic nonspecific diarrhea, which is a benign condition <sup>[1]</sup>, most cases of chronic diarrhea

are associated with malnutrition. In Saudi Arabia, data from Riyadh <sup>[2]</sup>, and Al Khobar <sup>[3]</sup> indicate that about 70% of the patients with chronic diarrhea present with signs of malnutrition. Inadequate caloric intake (anorexia, prolonged clear liquid or diluted formula feedings), loss of calories from malabsorption, and chronic inflammation are the main causes of malnutrition in patients with chronic diarrhea.

Malnutrition, when it is not rapidly reversed, is thought to increase the severity of diarrhea through a variety of mechanisms such as mucosal atrophy, increased susceptibility to infection, bacterial overgrowth which induces more mucosal damage and metabolizes bile acids, decreased pancreatic exocrine function, secondary disaccharidase deficiency (lactase, sucrase-isomaltase), and cow's milk protein intolerance <sup>[4],[5],[6],[7],[8],[9],[10],[11]</sup>. It is clear that these factors occurring singly or in combination can worsen the diarrhea and malabsorption, creating a cycle (diarrhea↔malnutrition) that must be broken in order to prevent deterioration and death.

## Management ▲

### Specific Therapy

There are two ways to break the cycle of diarrhea and malnutrition: stopping the diarrhea whenever possible and provision of nutritional support. For certain conditions, specific treatment provides adequate control of the diarrhea and rapid improvement of the nutritional status. The demonstration of prolonged bacterial infection (*E. coli*, *Salmonella* <sup>More Details</sup>) or infestation with *Giardia lamblia* allows for specific treatment. In addition, antibiotic therapy such as oral gentamicin combined with cholestyramine has been reported to be effective in stopping persistent diarrhea in infants, probably because of their effects on bacterial overgrowth; whereas metronidazole had no apparent effect <sup>[12]</sup>. However, where no specific organism has been demonstrated, gentamicin alone was not effective in the treatment of non-bloody persistent diarrhea and malnutrition <sup>[13]</sup>. Other modalities that might be considered in selected cases of secretory diarrhea include prostaglandin inhibitors (eg. salicylate) and steroids. Similarly, conditions like cow's milk protein intolerance, disaccharidase deficiency or monosaccharide malabsorption, and celiac disease are amenable to effective dietary elimination therapy. Spectacular response to specific treatment is usually seen in patients with acrodermatitis enteropathica and its variants after oral zinc therapy <sup>[14]</sup>. [\[Figure - 1\]](#), A and B, illustrate one of my patients before (11 months of age) and after treatment (6 years of age) respectively. This patient has acrodermatitis enteropathica variant with normal zinc blood levels that did not respond to regular doses of oral zinc (45 mg per day). However, dramatic response occurred after administration of zinc sulfate 250 mg daily which was subsequently reduced to almost weekly doses rather than smaller daily doses to improve compliance. Further attempts to reduce the frequency of treatment resulted in relapse indicating the need for lifelong therapy.

## Nutrition Therapy

Nutritional support is a true medical emergency for infants presenting with protracted diarrhea and severe malnutrition. After correction of water and electrolyte abnormalities, provision of nutrition is a priority in such patients, and should be started before, or simultaneously with tests or procedures necessary for etiologic diagnosis.

Prolonged periods of clear liquid or diluted formula feeding must be avoided in order to prevent worsening of nutritional status. Whenever possible, continuation of breast feeding, or provision of a short period of half strength formula feeding is recommended (by the WHO) during acute diarrheal diseases. This is well tolerated by most infants and contributes to the prevention of postinfectious chronic diarrhea and malnutrition [\[15\]](#).

The choice of type of nutrition and method of administration will vary according to the severity and suspected cause of the disease. For example, infants with clinical and laboratory evidence of disaccharidase deficiency should be fed a formula that does not contain the corresponding disaccharide (eg. lactose-free formula for patients with lactase deficiency). Similarly, feeding of non-cow's milk protein-containing formula is indicated for infants with suspected cow's milk protein intolerance (usually soy bean-based or elemental formula).

The introduction of elemental formulas has reduced the need for total parenteral nutrition for prolonged periods of time [\[16\]](#). The composition of those formulas is variable, but generally contain crystalline aminoacids or protein hydrolysates as sources of protein; glucose, sucrose, glucose oligomer and starch (to reduce osmolality); vegetable oil (long chain fatty acids) alone or with medium chain triglycerides. However, the assumption that these formulas are better absorbed than diets containing more complex nutrients is controversial. In fact, aminoacids may be better absorbed when given as oligopeptides than when administered as aminoacid mixture [\[17\]](#). Nevertheless, these formulas are either not available or too expensive to be affordable in developing countries where they are most needed. Recent reports indicate that chicken- based formulas are effective substitutes to elemental formulas in protracted diarrhea and severe malnutrition [\[18\]](#).

The preferred method for feeding is the intermittent oral intake, but for infants with chronic diarrhea and malnutrition, nasogastric feeding is widely used. Until recently, nasogastric feeding was given as intermittent bolus feeds by gravity drip. However, continuous administration of formula by infusion pumps has been recently shown to be superior to the intermittent technique in terms of enteral balance and weight gain. Continuous intragastric feeding is well tolerated by many infants who did not tolerate the intermittent bolus feeding technique, thereby reducing the need for total parenteral nutrition [\[19\]](#).

Parenteral nutrition is still required in the initial stages of treatment by some patients. Partial parenteral nutrition is commonly used to provide additional calories to infants who are able to tolerate limited amounts of nutrients. Total parenteral nutrition (TPN), unlike partial nutrition which is given through peripheral veins, is possible only through a central vein. It should be considered the last alternative technique of

nutritional support. It is very effective in providing sufficient calories to reverse malnutrition when all other means have failed. Parenteral nutrition is even more effective when given with oral feeds even in small amounts <sup>[20]</sup>. Nevertheless, TPN is not without hazards. Sepsis and liver disease are among the most serious side effects that may be life-threatening.

In many infants, the response to nutritional therapy is dramatic. An example is illustrated by one of my patients with the diagnosis of severe postenteritis syndrome. [\[Figure - 2\]A](#) is self-explanatory showing severe malnutrition on admission. After a period of nutritional support using a combination of oral elemental formula and partial peripheral intravenous nutrition, gradual introduction of normal diet for age was tolerated and [\[Figure - 2\]B](#) was taken after several weeks on regular diet. This patient not only remained asymptomatic but continued to gain weight on normal diet for age.

## References

1. Davidson M, Wasserman R. The irritable colon of childhood (chronic nonspecific diarrhea syndrome). *J Pediatr* 1966;69:1027-8. [↑](#)
2. Abdullah AMA. Aetiology of chronic diarrhea in children: Experience at King Khaled University Hospital, Riyadh, Saudi Arabia. *Annals of Tropical Pediatrics* 1994 (In Press). [↑](#)
3. El Mouzan MI. Chronic diarrhea in children: Physiology pathophysiology and etiology. *Saudi J Gastroenterol* 1995;1(1):37-42. [↑](#)
4. Stanfield JP, Huth MSR, Tunnicliffe R. Intestinal biopsy in Kwashiorkor. *Lancet* 1965;II:519-23. [↑](#)
5. Burman D. The jejunal mucosa in Kwashiorkor. *Arch Dis Child* 1965;40:526-31. [↑](#) [\[PUBMED\]](#)
6. Udall JN, Suskind RM. Altered gastrointestinal immunity in malnourished children. In: Gracey M, ed. *Diarrheal disease and malnutrition: A clinical update*. Edinburgh: Churchill Livingstone 1985:30-46. [↑](#)
7. Challacombe DN, Richardson JM, Rowe B, Anderson CM. Bacterial microflora of the upper gastrointestinal tract in infants with protracted diarrhea. *Arch Dis Child* 1974;49:270-7. [↑](#)
8. Schneider RE, Viteri FE. Luminal events of lipid absorption in protein-calorie malnourished children: relationship with nutritional recovery and diarrhea. II: Alterations in bile acid content of duodenal aspirates. *Am J Clin Nutr* 1974;27:788-96. [↑](#)
9. Barbezat GO, Hausen JDL. The exocrine pancreas and protein-calorie malnutrition. *Pediatrics* 1968;42:77-92. [↑](#)
10. Romer H, Uroboch R, Gomez MA et al. Moderate and severe protein-energy malnutrition in childhood: effects on jejunal mucosal morphology and disaccharidase activities. *JPEN* 1983; 2:459-64. [↑](#)
11. Rothman D, Latham MC, Walker WA. Transport of macromolecules in malnourished animals. I: Evidence for increased uptake of antigens. *Nutr Res* 1982;2:467-73. [↑](#)
12. Hill ID, Mann MD, Househam KC, Bowie MD. Use of oral gentamicin, metronidazole and cholestyramine in the treatment of severe persistent diarrhea in infants. *Pediatrics* 1986;77:471-81. [↑](#)
13. Bhatnagar S, Bhan MK, Sazawal S, et al. Efficacy of massive doses of oral

- gentamicin therapy in nonbloody persistent diarrhea with associated malnutrition. *J. Pediatr Gastroenterol and Nutr* 1992;12:117-24. †
14. Krieger I, Evans GW, Zelkowitz PS. Zinc dependency as a cause of chronic diarrhea in variant acrodermatitis enteropathica. *Pediatrics* 1982;69(6):773-7. †
  15. World Health Organization 1984; WHO/CDD/SER/80-2, rev 1. †
  16. Orsenstein SR. Enteral versus parenteral therapy for intractable diarrhea of infancy: A prospective, randomized trial. *J Pediatr* 1986;109:277-86. †
  17. Kleinman RE, Galeano NF, Ghishan F, et al. Nutrition management of chronic diarrhea and/or malabsorption. *J Pediatr Gastroenterol and Nutr* 1989;9:407-15. †
  18. Godard C, Bustos M, Munoz M, Nussle D. Value of a chicken-based formula for refeeding of children with protracted diarrhea and malnutrition in a developing country. *J Pediatr Gastroenterol and Nutr* 1989;9:473-80. †
  19. Parker P, Stroops S, Greene H. A controlled comparison of continuous versus intermittent feeding in the treatment of infants with intestinal disease. *J. Pediatr* 1981;99:360-4. †
  20. Greene HL, McCabe DR, Merenstein GB. Protracted diarrhea and malnutrition in infancy: changes in intestinal morphology and disaccharidase activities during treatment with total intravenous nutrition or oral elemental diets. *J. Pediatr* 1975;87(5):695-704. †

---

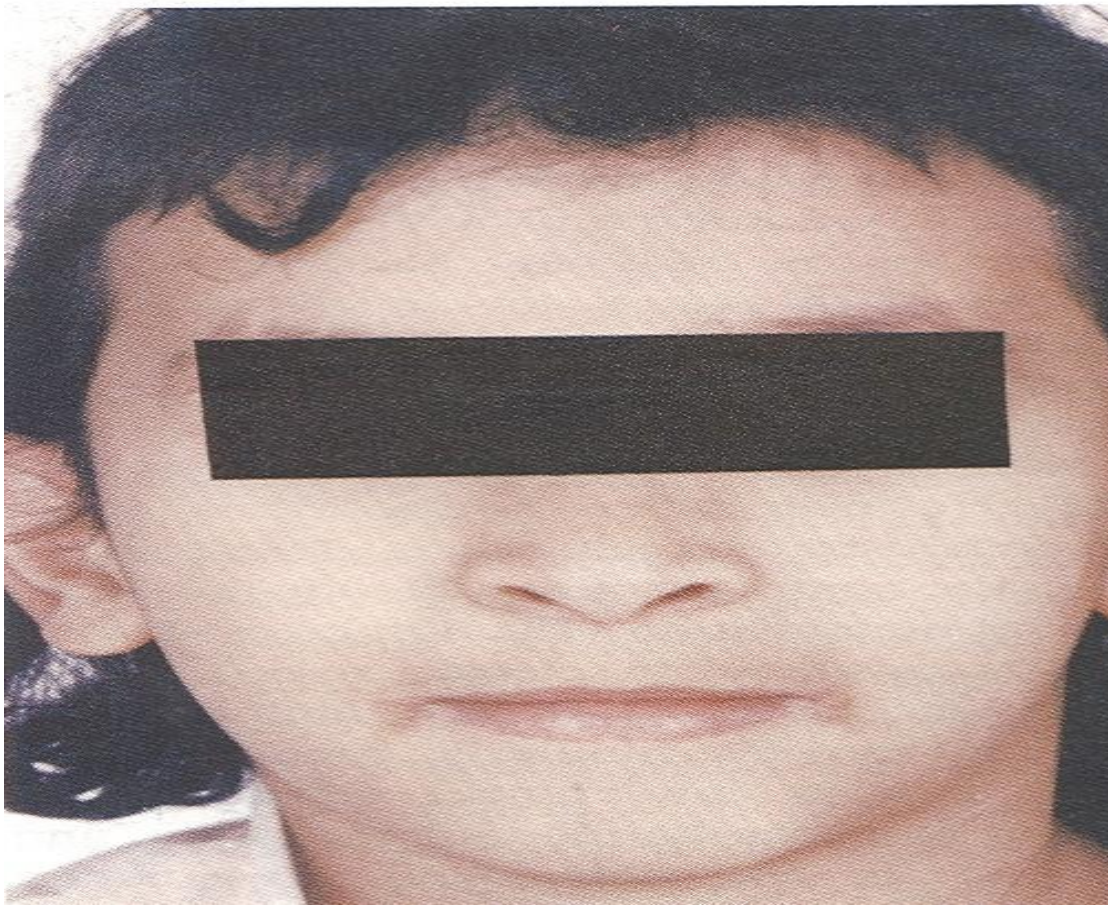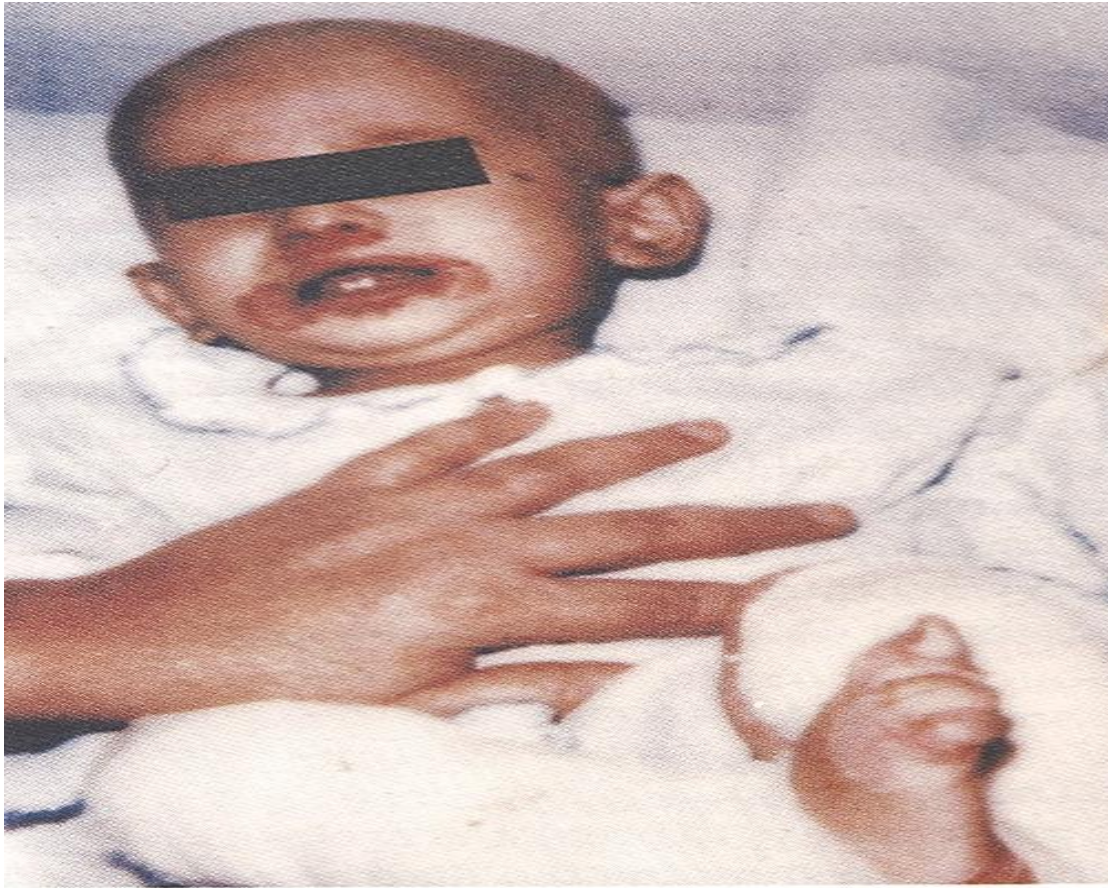**Correspondence Address:**

Mohamed I El Mouzan

Department of Pediatrics, College of Medicine, King Saud University, P.O. Box 2925(39), Riyadh 11461

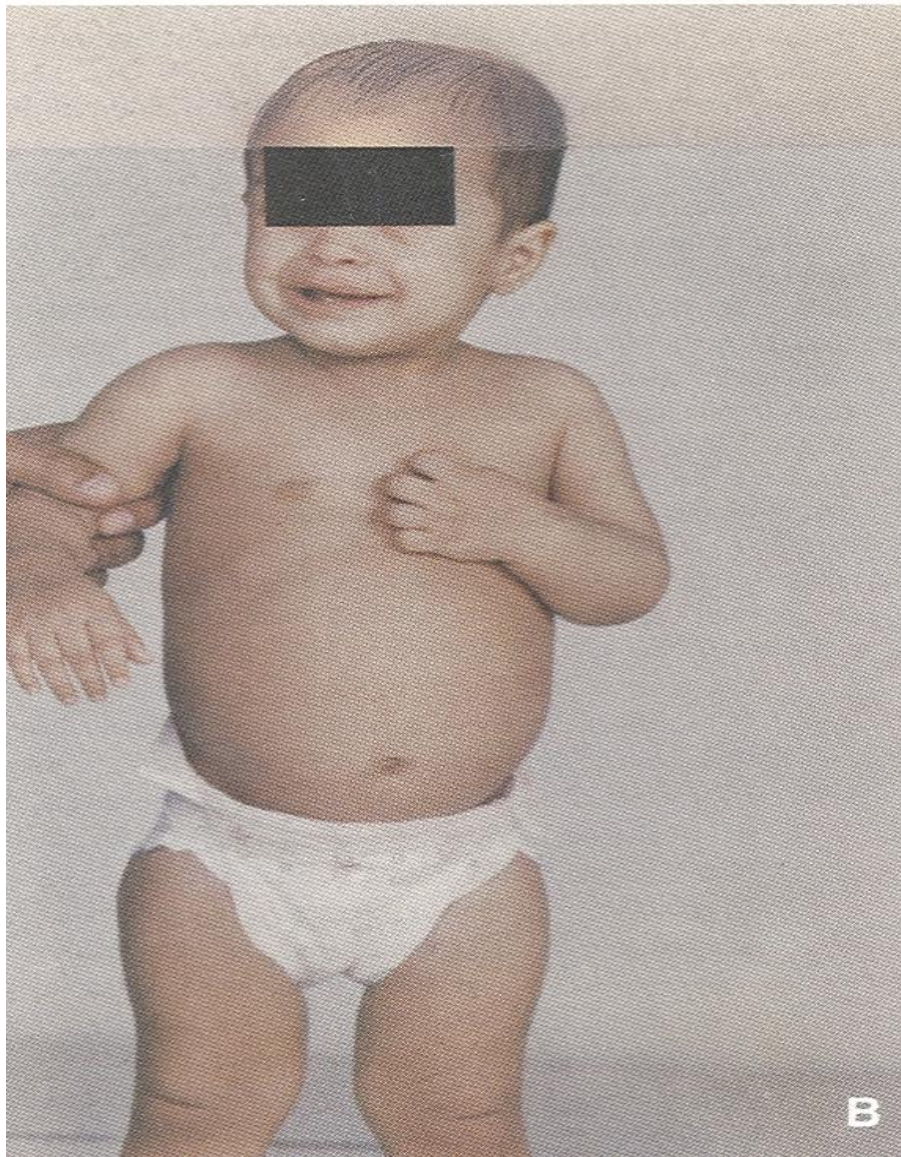
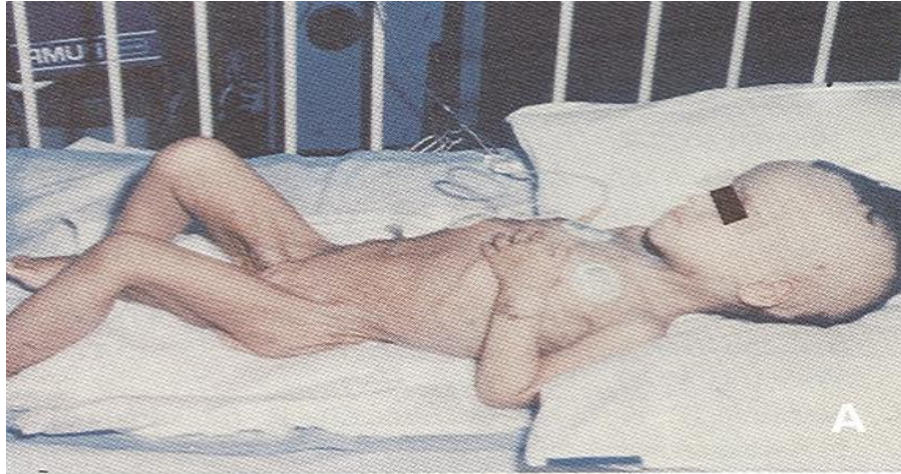Saudi Arabia

**Figure 1. Acrodermatitis enteropathica. A. - Chronic diarrhea and perioral skin lesions. Also the patient had conjunctivitis nail dystrophy and severe perianal rash. B. - Response to oral zinc therapy. Same patient at 6 years of age. No skin lesions or diarrhea. Normal growth and development on weekly zinc therapy.**





**Figure 2. Postenteritis syndrome. A. - Severe malnutrition secondary to chronic diarrhea of two months duration in a previously healthy infant. B. - Same patient after nutritional support. tolerating a normal diet for age with no diarrhea and adequate weight gain.**



**Table 1: Investigations in Chronic Diarrhea**

---

**First line tests (Routine):**

- Blood: CBC and differential, ESR
- Urine: Microscopy and culture
- Stool: Occult blood, microscopy and culture. Fat, pH reducing substances. Steatocrit.

**Second line tests (Special):**

- Serum electrolytes, blood gases, serum carotene.
  - Cholesterol, triglycerides, serum zinc level.
  - Lipoprotein electrophoresis. Total serum protein and min.
  - Antigliadin antibodies.
  - Barium meal with small bowel follow-through. Ba enema.
  - D-Xylose test. Sweat chloride.
  - Tests for immunodeficiency (congenital, acquired)
  - Small bowel biopsy.
  - Rectosigmoidoscopy and biopsy.
  - Hormone levels in the serum or urine.
  - Elimination and challenge tests.
-